

Unusual Cause of Small Bowel Obstruction: Small Bowel Incarceration Through Uterine Perforation

Sami K* and Sonia M

¹Department of Radiology, Military Hospital of Tunis, TUNISIA, Faculty of medicine Tunis University Tunis El Manar TUNISIA

Volume 4 Issue 13- 2020

Received Date: 20 Aug 2020

Accepted Date: 06 Sep 2020

Published Date: 10 Sep 2020

1. Abstract

Among the causes of small bowel obstruction, the incarceration of a bowel loop through uterine perforation is extremely rare. The purpose of our report is to illustrate the contribution of sonography in diagnosing this unusual surgical emergency through the case of a 28-year-old patient who was referred to our department a month after dilation and curettage for small bowel obstruction.

2. Keywords

Small bowel obstruction; Pregnancy-uterin; Perforation-ultrasonography

3. Introduction

Small bowel obstruction is a significant surgical problem that represents 20% of surgical admissions for acute abdominal pain. It's caused by postoperative adhesions in 70% of all cases [1]. Other causes include hernias, neoplasms, and inflammatory bowel disease. Obstruction due to small bowel incarceration through uterine perforation is exceptional and has been described as a complication of dilation and curettage notably for postpartum placenta retention. It is surgical emergency and the delay in diagnosis and treatment has deleterious consequences for the mother. Ultrasound is often the initial diagnostic modality to be used for evaluation of uterine perforation as it is a simple and low-cost technique that can be performed on an emergency basis. It may demonstrate indirect findings like visualization of bowel loops in myometrial or endometrial cavity or even demonstrate the site of uterine rupture.

4. Case Presentation

A 28-year-old woman, gravida 2, para 2, was referred to the emergency department for intermittent abdominal pain, inability to have a bowel movement or pass gas and swelling of the abdomen. She had an obstetric history of two vaginal births. She had undergone dilation and curettage for post-partum retained placenta a month before the present examination. On initial physical examination, she was afebrile with normal vital signs. The abdomen was soft, mildly distended, with active bowel sounds, and was diffusely tender to palpation without guarding or rebound tenderness. Blood examination did not show any abnormality. Initially, a transabdominal ultrasound of the pelvis was performed and a tubular-shaped irregular echogenic tissue was seen within the endometrial cavity. For further evaluation, transvaginal ultrasound of the pelvis was then performed showing fluid-filled tubular structure within the uterine cavity with serpiginous structure reminis-

cent of convoluted valves (Figure 1,3). It also showed a distended small-bowel loop containing echogenic material beside the uterus (Figure 1) and the pouch of Douglas was filled with fluid (Figure 2). The patient was taken to the operative suite due to the possibility of uterine perforation. Laparotomy demonstrated a defect in the uterus containing an incarcerated loop of small bowel and mesenteric fat. The involved entrapped bowel was debrided and the uterine incision was sutured with uneventful postoperative course.

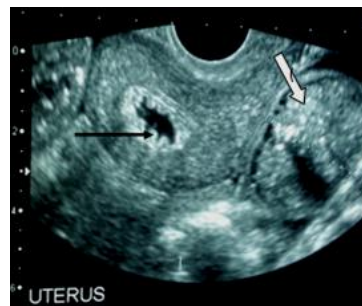


Figure 1: Longitudinal endouterine ultrasound scan showing serpiginous structure within the uterine cavity related to convoluted valves (→) and distended small-bowel loop containing echogenic material beside the uterus (←).

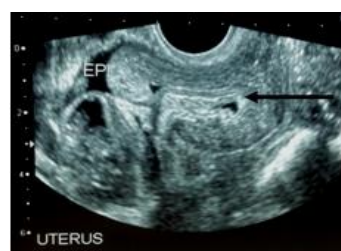


Figure 2: Endouterine ultrasound scan showing small intestine loop within the uterine cavity (→) and free fluid within the pouch of Douglas (←).

*Corresponding Author (s): Kouki Sami, Department of Radiology, Military Hospital of Tunis, TUNISIA, Faculty of medicine Tunis University Tunis El Manar TUNISIA, Tel: 0021698660361, E-mail: koukiseimi@yahoo.fr; sonia.moueddeb@gmail.com

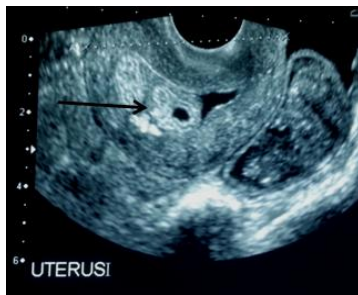

Figure 3: Longitudinal ultrasound scan showing tubular fluid-filled structure within the uterus (→).

5. Discussion

Small bowel obstruction is a frequently encountered problem in general surgery. The most common cause of small bowel obstruction is post-operative adhesion formation. It has been estimated that up to 70% of cases of small bowel obstruction are due to adhesions [1] followed by obstruction as malignancy. Other less common causes are obstruction due to inflammation, bezoars, intussusceptions, congenital bands and volvulus [2].

Small bowel obstruction caused by uterine perforation due to dilation and curettage (D&C) is extremely rare. D&C is relatively safe with a low overall complication rate of 0.7% [3]. The rate of perforation varies with the indication for the procedure. Perforation is most common when attempting control of postpartum hemorrhage (5.1%) and is less frequent during diagnostic curettage (0.3% in the premenopausal patient and 2.6% in the postmenopausal patient).

Several risk factors for uterine perforation have been identified [4]: advanced maternal age, greater parity, history of prior abortion or cesarean section, retroverted uterus, history of previous cone biopsy, failure to use ultrasound, and underestimation of the duration of pregnancy. In our present case, none of these factors has been identified. The perforation might be due to lack of surgery experience which has been recognized as the strongest statistically significant risk factor for perforation.

In most cases, the perforation is diagnosed during the curettage or a few days after the procedure. It appears, however, that a fair number of uterine perforations pass by undetected.

Delayed presentation of uterine perforation after dilation and curettage is extremely rare. In our case, uterine perforation with bowel incarceration was diagnosed and treated a month after dilation and curettage. The perforation site might have been covered with the omentum, leading to delayed presentation of obstruction.

In the emergently presenting patient, ultrasound is the preferred diagnostic modality.

In our case, transvaginal sonography has been more specific than

transabdominal pelvic ultrasound for diagnosis. It showed serpiginous, fluid-filled tubular structures within the uterus corresponding to the incarcerated small bowel loop. In some cases, it may show small echogenic focus suggesting the presence of air, adjacent material of increased echogenicity suggesting mesenteric fat or even the uterine defect [5].

In our present case, ultrasound also objected a tubular structure beside the uterus containing echogenic material. In our review of the literature, there was no description of this sign. We can suppose that it's the sonographic equivalent of the "feces sign" described in CT.

6. Acknowledgment

We thank Alaa kouki for the grammar checking. Finally, Monia Bahri who was the main organizational organ of this work.

References

1. Maglinte DD, Balthazar EJ, Kelvin FM, Megibow AJ. The role of radiology in the diagnosis of small-bowel obstruction. *AJR*. 1997; 168(5): 1171-80.
2. Wilson MS, Ellis H, Menzies D, Moran BJ, Parker MC, Thompson JN. A review of the management of small bowel obstruction. Members of the Surgical and Clinical Adhesions Research Study (SCAR). *Ann R Coll Surg Engl*. 1999; 81(5): 320-8.
3. Gakhil MS, Levy HM. Sonographic diagnosis of extruded fetal parts from uterine perforation in the retroperitoneal pelvis after termination of intrauterine pregnancy that were occult on magnetic resonance imaging. *J Ultrasound Med*. 2009; 28(12): 1723-1727.
4. Coughlin LM, Sparks DA, Chase DM, Smith J. Incarcerated small bowel associated with elective abortion uterine perforation. *J Emerg Med*. 2013; 44(3): e303-6.
5. Shulman SG, Bell CL, Hampf FE. Uterine perforation and small bowel incarceration bowel incarceration: sonographic and surgical findings. *Emerg Radiol*. 2006; 3(1):43-5.